

비충전술후에 비강에 발생한 거대한 화농성 육아종 1례

이흥만 · 강희준 · 이상학 · 황순재

A Giant Pyogenic Granuloma of the Nasal Cavity Complicated
from Nasal Packing

Heung-Man Lee, MD, Hee Joon Kang, MD, Sang Hag Lee, MD and Soon Jae Hwang, MD

Department of Otorhinolaryngology-Head and Neck Surgery, Korea University College of Medicine,
Seoul, Korea

- ABSTRACT -

Nasal packing is common procedure in the rhinologic service for nasal bleeding and postoperative hemostasis. However, pyogenic granuloma complicated from nasal packing has rarely been reported in the literature. A case of a giant pyogenic granuloma of the inferior turbinate secondary to nasal packing is presented and its removal via an endoscopic approach is detailed. The nasal endoscope provided excellent visualization and operative control during excision, obviating the need for a lateral rhinotomy. Furthermore, to prevent complications and decrease the discomfort, we strongly recommended the use of non-traumatic materials for nasal packing. Rhinologist should be aware of this disease entity when encountered with patients presenting with nasal obstruction after a history of nasal packing. (*J Clinical Otolaryngol* 2001;12:254-257)

KEY WORDS : Pyogenic granuloma · Nasal cavity · Endoscopic sinus surgery · Epistaxis.

서 론

(botryomycoma)
Hartzell(1904)
1)²⁾

가 .
6)⁷⁾
1

3-5)
(nasal packing)

증 례

: 2001 8 10

: 2001 8 20

: , 152 - 703

80

56

가

: (02) 818 - 6750 · : (02) 868 - 0475

E - mail : hmlee91@hotmail.com

3

(Fig. 1).

(PNS CT)

density)

. 2

(soft tissue
(Fig. 2).

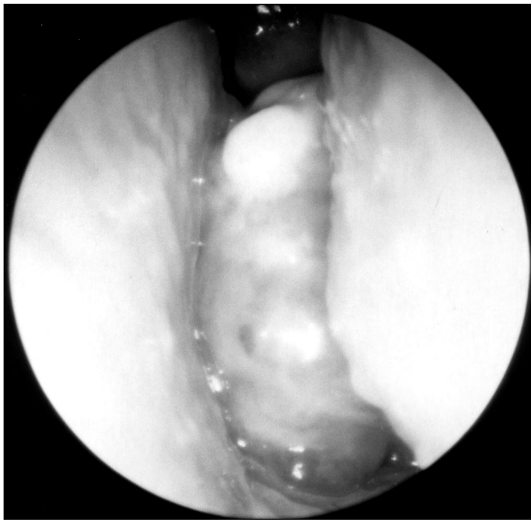


Fig. 1. Endoscopic view of the lesion showing an irregular surfaced, dark-brown colored, and easily bleeding mass arising from the posterior part of the left inferior turbinate.

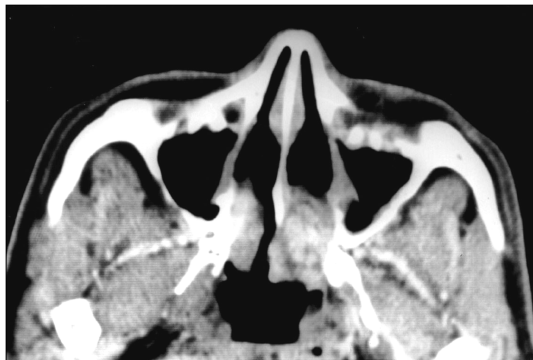


Fig. 2. Axial computed tomography of paranasal sinuses showing a soft tissue density mass in the left nasal cavity.

2.5 x 1.5 cm

(Fig. 3),

(trabecule)
(venule)

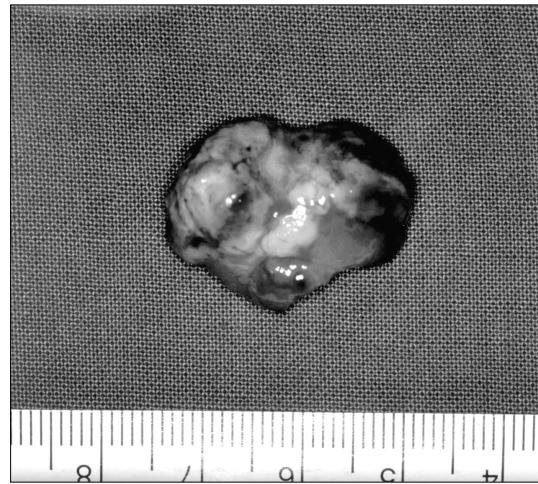


Fig. 3. The surgical specimen revealed a dark brown pyogenic granuloma attached to the posterior part of the left inferior turbinate.

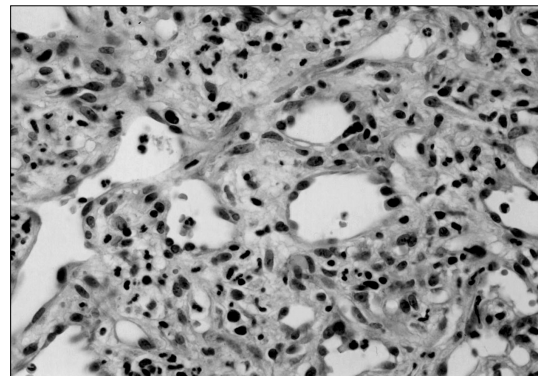


Fig. 4. Photomicrograph of the pyogenic granuloma showing lobular cellular hemangioma set in a fibromyxoid stroma. Hematoxylin and eosin stain, x 400 original magnification.

(Fig. 4), (stromal edema) 가 .

1 . 2

고 찰 6)7)

1 20

2 .

capillary hemangioma) , (lobular (inflatable balloon) (expandible ma-
terial) 가

8) (cluster) , (petrolatum - based) myosperulosis

13)14)

(fibrinoid exudates) .

가

9) 가 , , 가

3-5)

12) 가

10) Whittaker 11) , 9)

가 가 12)

가 가 ,

15% 5)

가 가 8)

가

중심 단어 :

REFERENCES

- 1) Montgomery DW, Culver GD. *Granuloma pyogenicum*. *Arch Dermatol Syphilol* 1932;26:131-8.
- 2) Michelson H. *Granuloma pyogenicum*. *Arch Dermatol Syphilol* 1925;12:492-505.
- 3) Kerr D. *Granuloma pyogenicum*. *Oral Surg Med Oral Pathol* 1951;4:158-76.
- 4) Angelopoulos AP. *Pyogenic granuloma of the oral cavity: statistical analysis of its clinical features*. *J Oral Surg* 1971;29:840-7.
- 5) Bhaskar SN, Jacoway JR. *Pyogenic granuloma-clinical features, incidence, histology, and result of treatment: report of 242 cases*. *J Oral Surg* 1966;24:391-8.
- 6) Sheen TS, Ko JY, Hsu YH. *Pyogenic granuloma-an uncommon complication of nasal packing*. *Am J Rhinol* 1997;11:225-7.
- 7) Bhattacharyya N, Wenokur RK, Goodman ML. *Endoscopic excision of a giant pyogenic granuloma of the nasal cavity caused by nasal packing*. *Rhinology* 1997;35:44-5.
- 8) Miller FR, D'Agostino MA, Schlack K. *Lobular capillary hemangioma of the nasal cavity*. *Otolaryngol Head Neck Surg* 1999;120:783-4.
- 9) Lance E, Schatz C, Nach R, Thomas P. *Pyogenic granuloma gravidarum of the nasal fossa: CT features*. *J Comput Assist Tomogr* 1992;16:663-4.
- 10) Mussali NG, Hopps RM, Johnson NW. *Oral pyogenic granuloma as a complication of pregnancy and the use of hormonal contraceptives*. *Int J Gynecol Obst* 1976;14:187-91.
- 11) Whitaker SB, Bouquot JE, Alimario AE, Whitaker TJ Jr. *Identification and semiquantification of estrogen and progesterone receptors in pyogenic granulomas of pregnancy*. *Oral Surg Oral Med Oral Pathol* 1994;78:755-60.
- 12) Manus DA, Sherbert D, Jackson IT. *Management considerations for the granuloma of pregnancy*. *Plast Reconstr Surg* 1995;95:1045-50.
- 13) Kyriakos M. *Myospherulosis of the paranasal sinuses, nose and middle ear. A possible iatrogenic disease*. *Am J Clin Pathol* 1977;67:118-30.
- 14) Wheeler TM, Sessions RB, McGavran MH. *Myospherulosis: a preventable iatrogenic nasal and paranasal entity*. *Arch Otolaryngol* 1980;106:272-4.